

Learn the Brachial Plexus in Five Minutes or Less

By Daniel S. Romm, M.D.

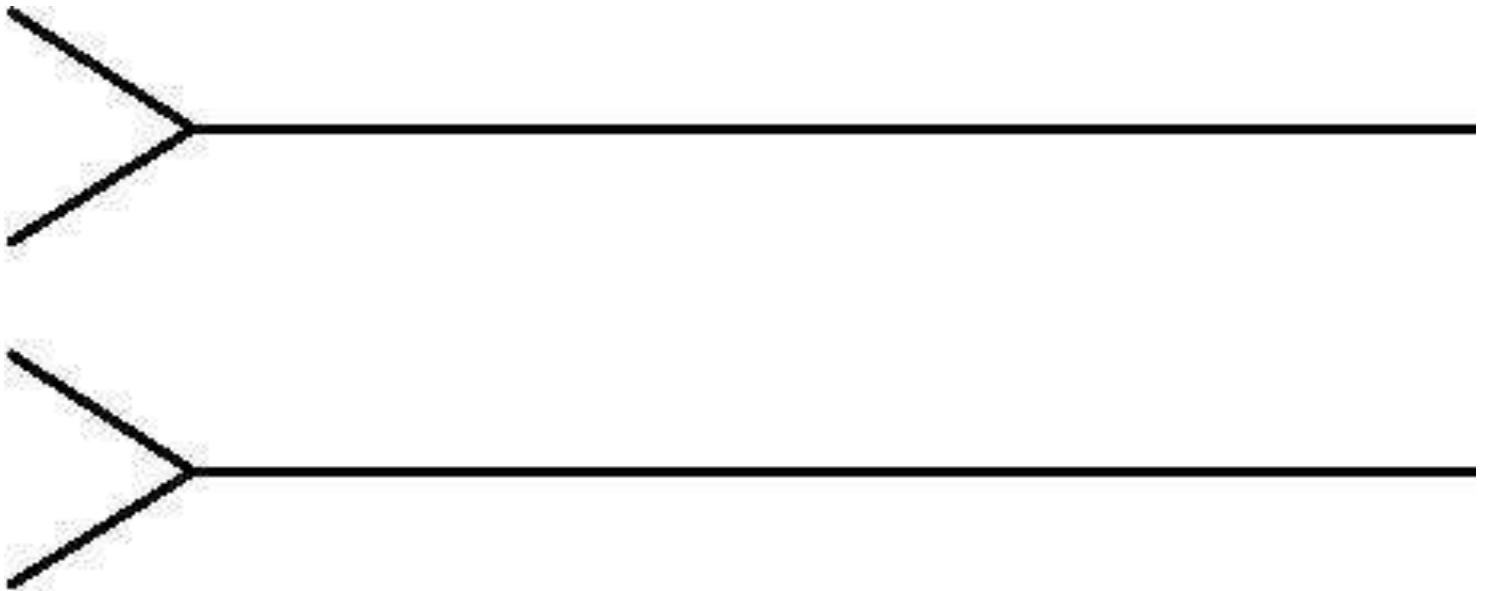
Chief, Physical Medicine and Rehabilitation
Department of Veterans Affairs, Biloxi, Mississippi
and **Dennis A. Chu, M.D.**

This material is the result of work supported with resources and the use of facilities at the VA Gulf Coast Veterans Health Care System. This material reflects the authors' personal views and in no way represents the official view of the Department of Veterans Affairs of the U.S. Government.


The brachial plexus contains the neural connections between the neck and brachial nerves.

This speedy method helps simplify understanding the diagram of the brachial plexus.

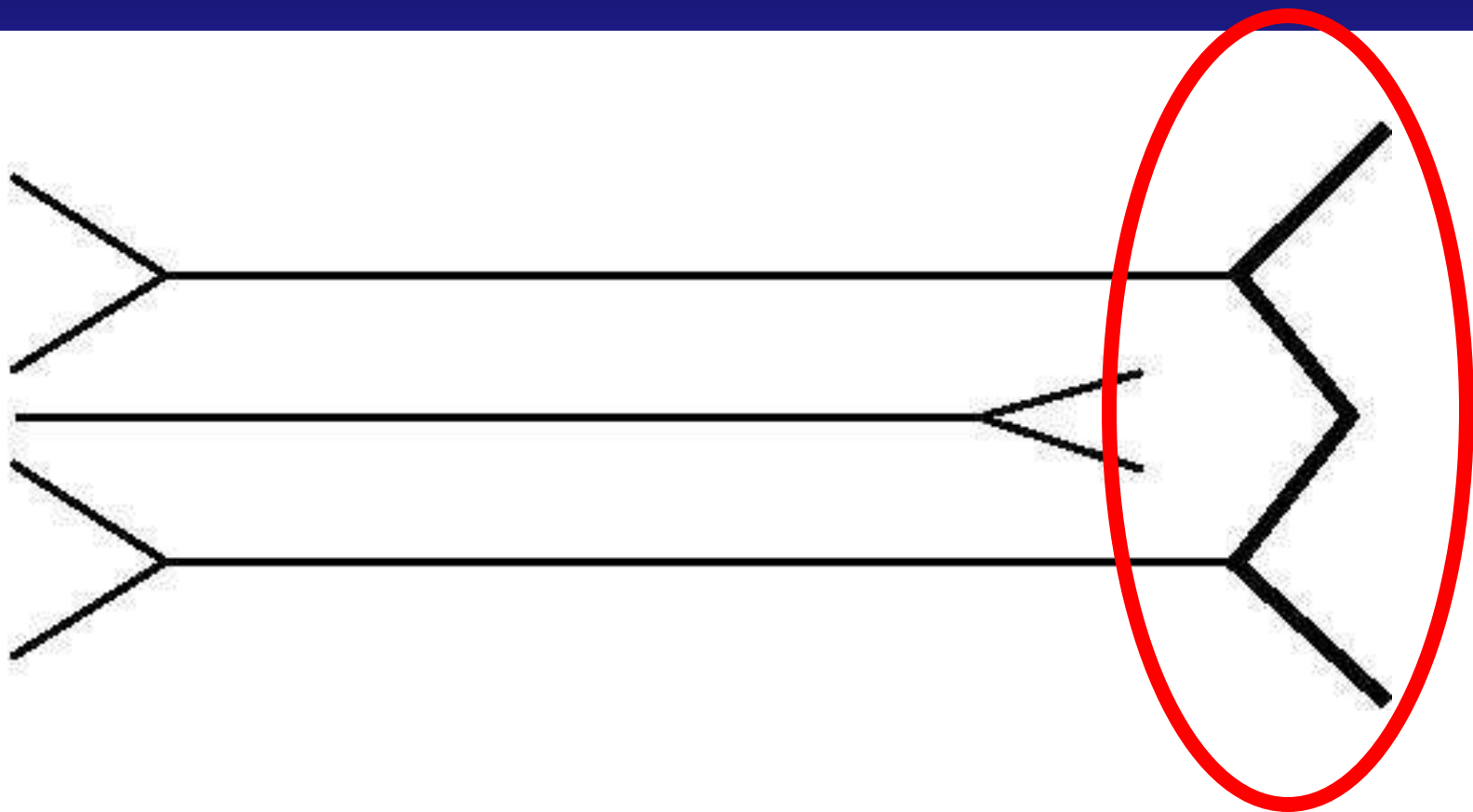
Draw two headless arrows to the right.



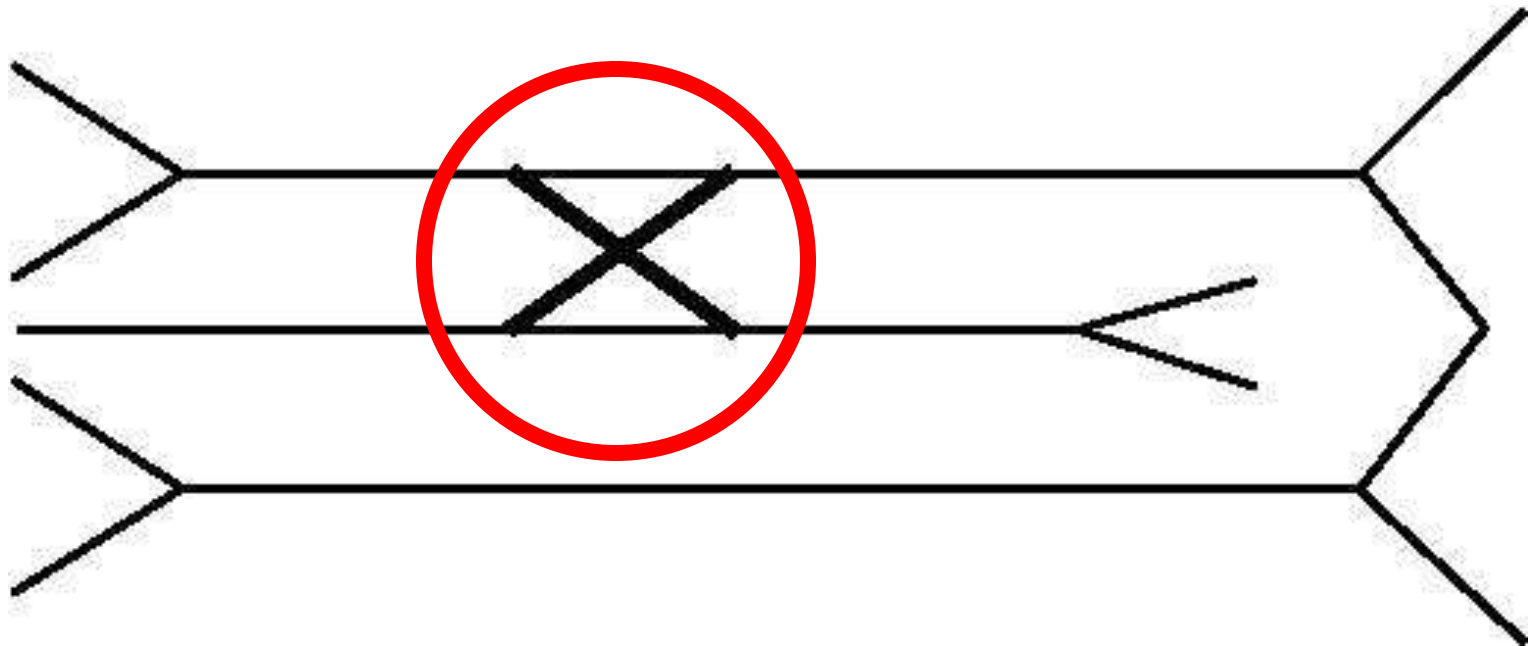
Add a headless arrow to the left.



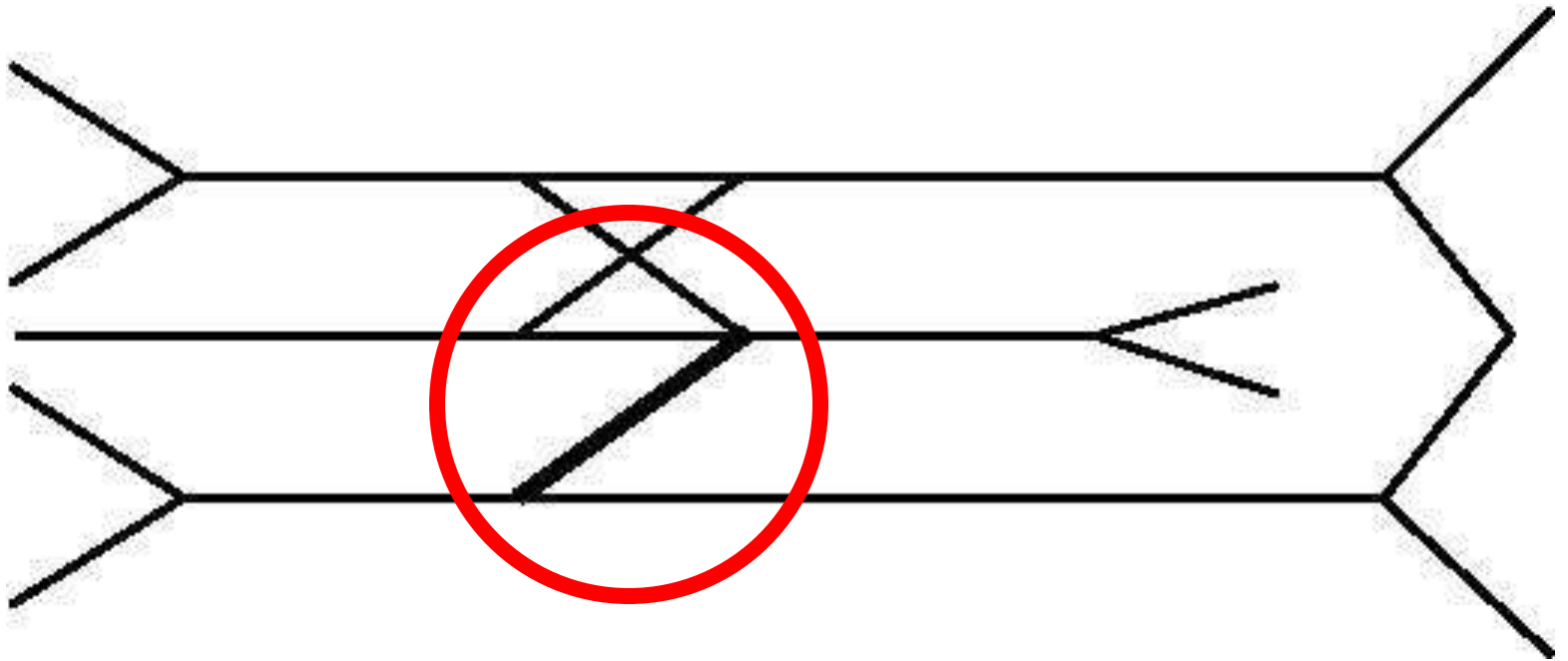
Add a "W".



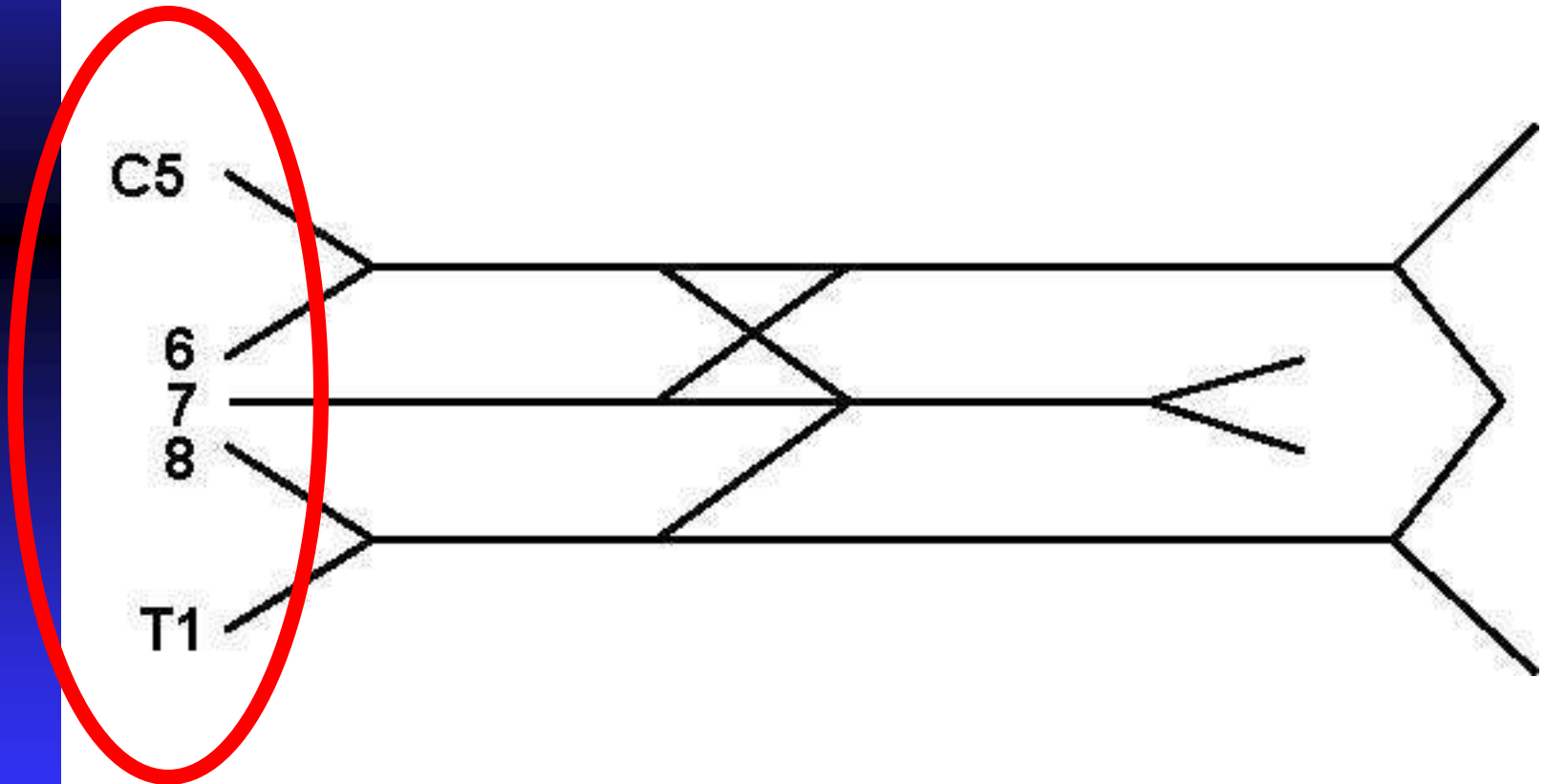
Add an "X".



Add a "Y". (Just a branch of the "Y" is added.)



Label C5 to T1.

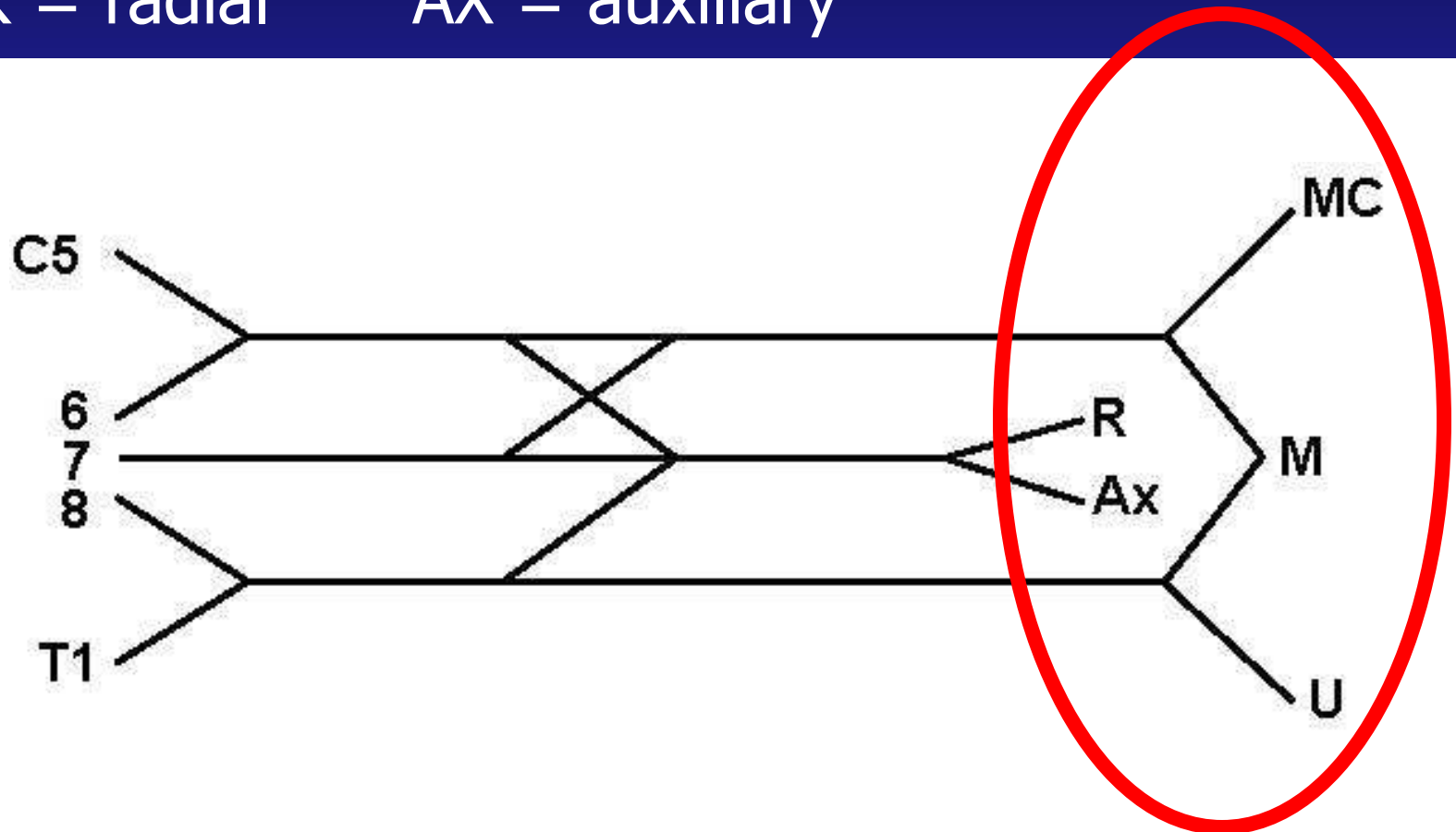


Label the major branches:

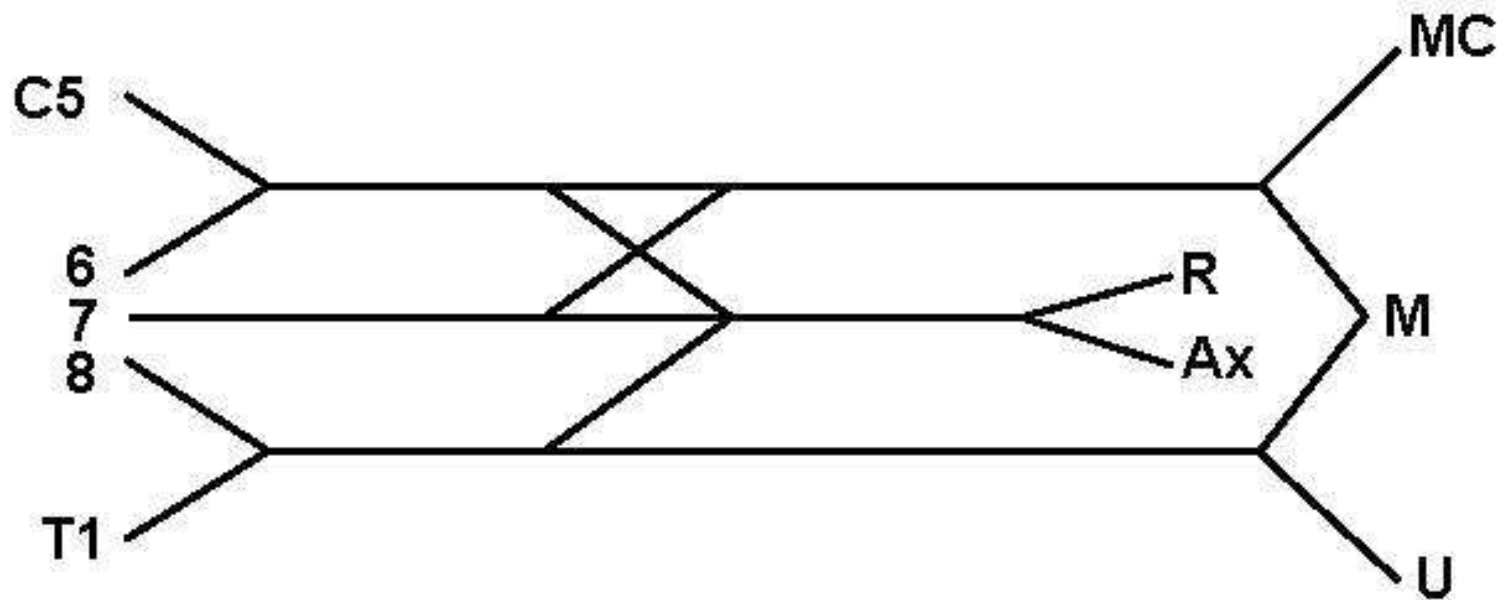
MC = musculocutaneous,

M = median U = ulnar

R = radial AX = auxiliary



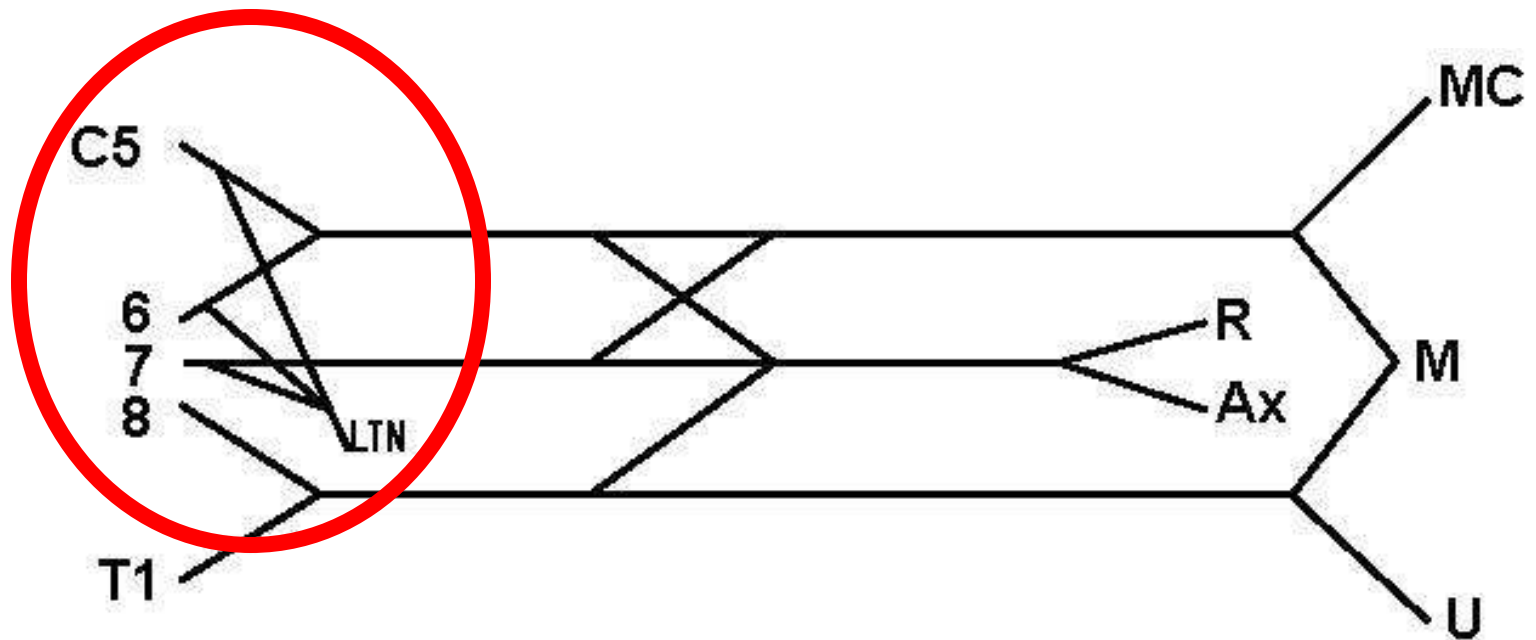
This diagram includes the main branches and main nerve roots with the proper connections.



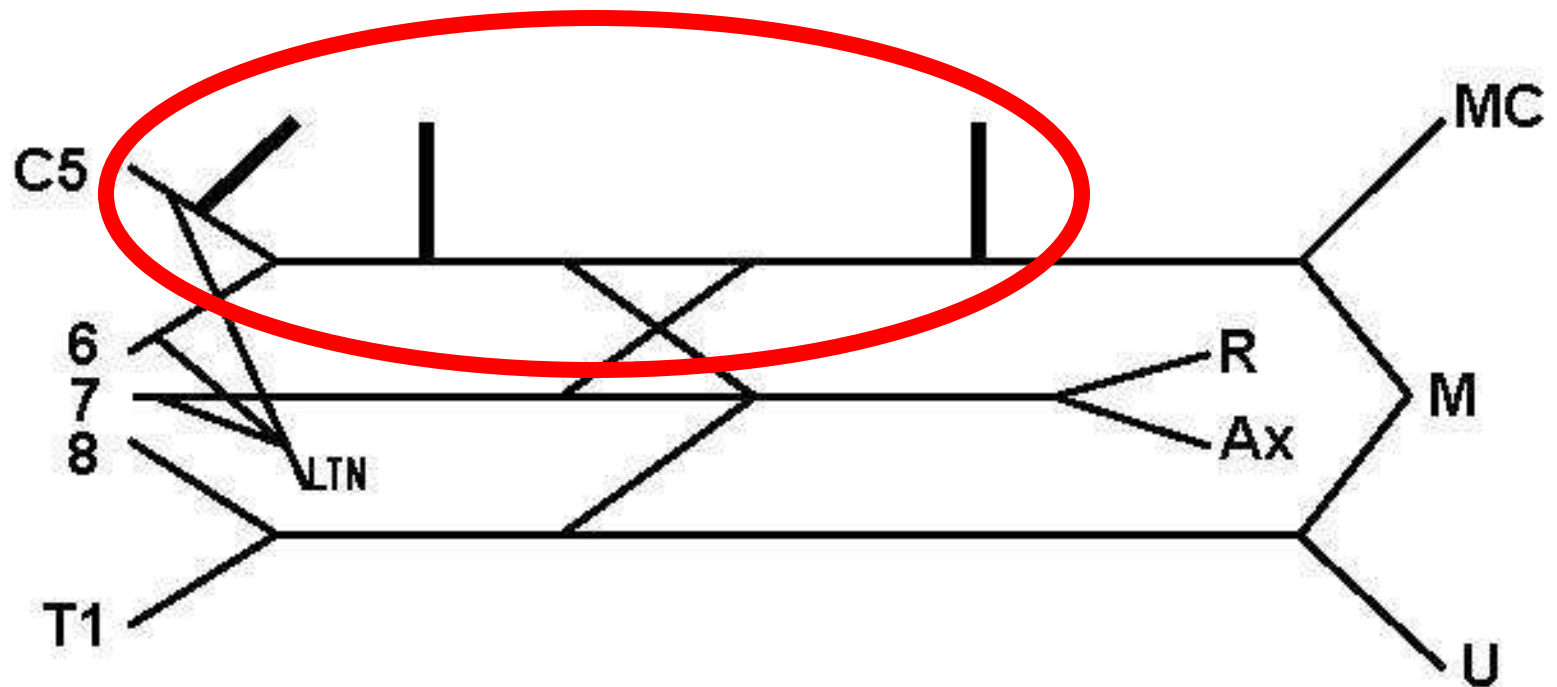
More complex diagramming of the brachial plexus includes the four "3s."

Neurosurgeons, neurologists, and physiatrists will use this diagram system.

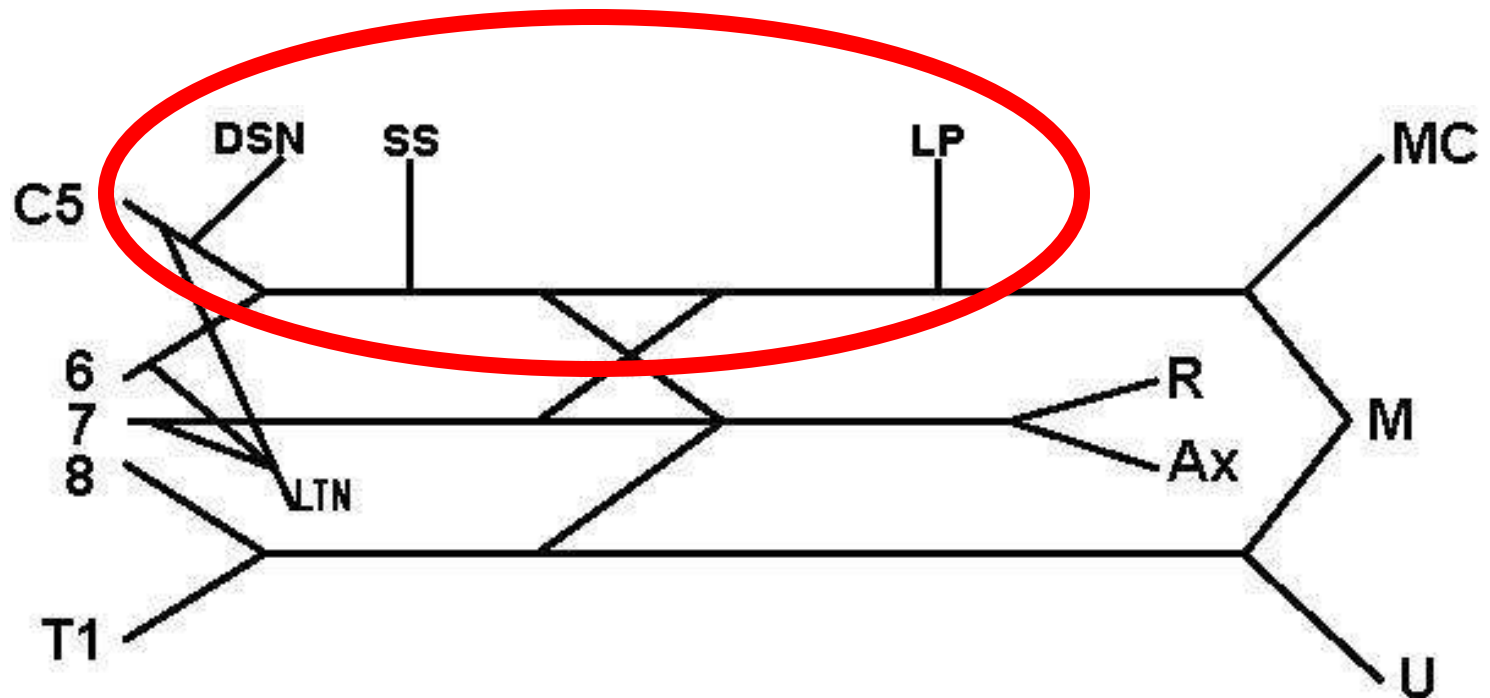
The first "3" is the branches to C5, 6, and 7 which form LTN = long thoracic nerve.



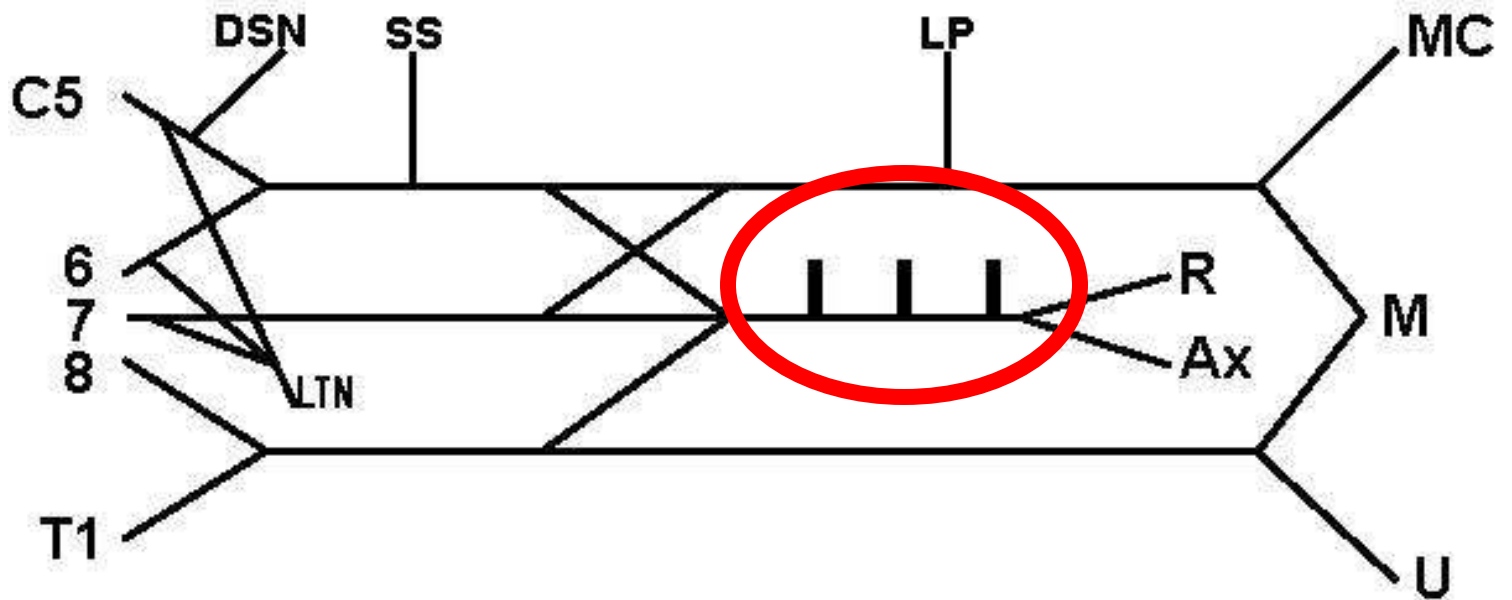
Next, each of the headless arrows has three nerves attached to it. To the top headless arrow, add its "3."



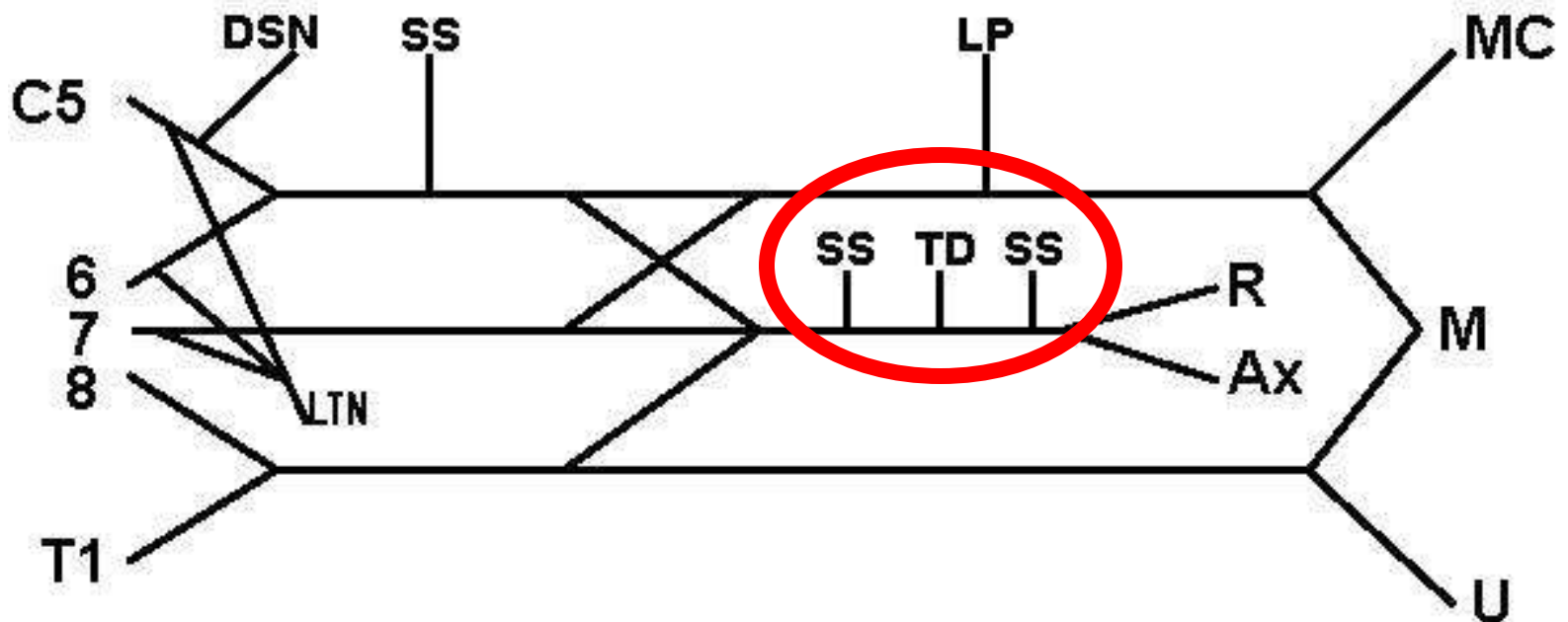
Label these "3": DSN = dorsoscapular nerve;
SS = suprascapular nerve;
LP = lateral pectoral nerve.



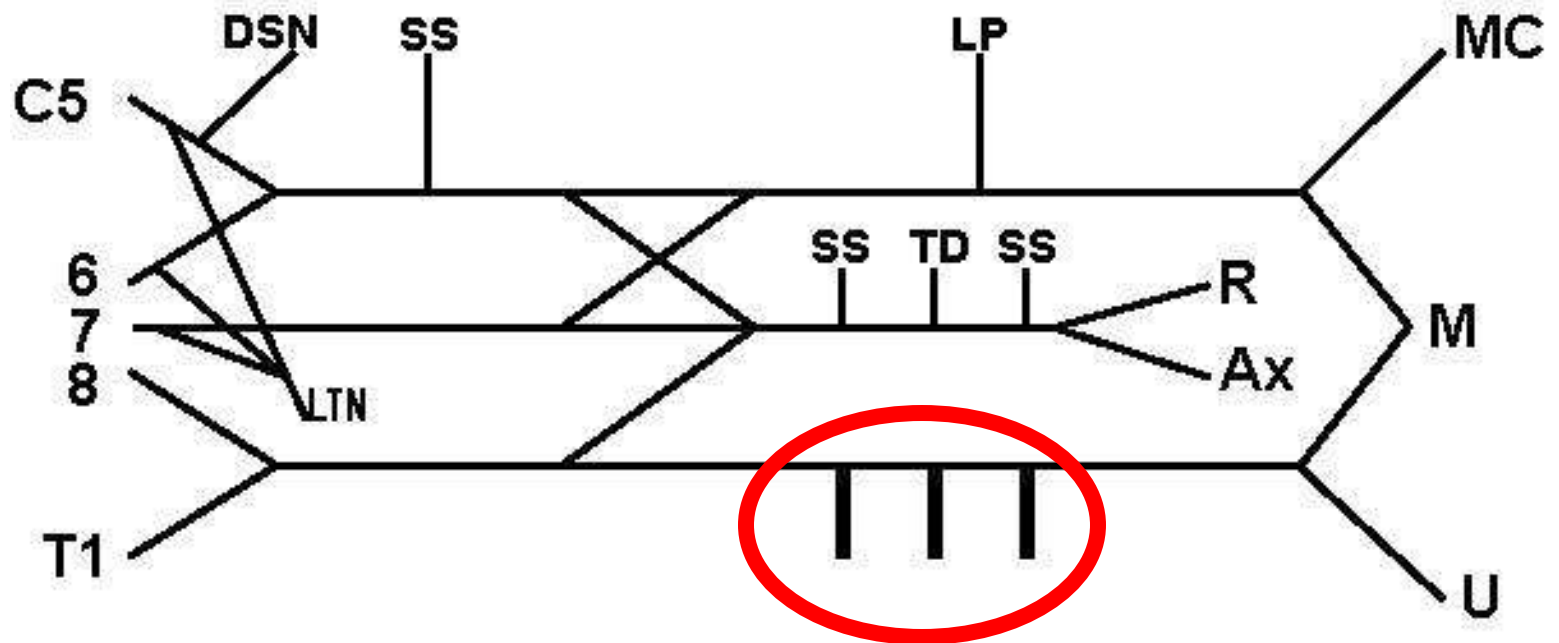
Add the "3" to the middle headless arrow.



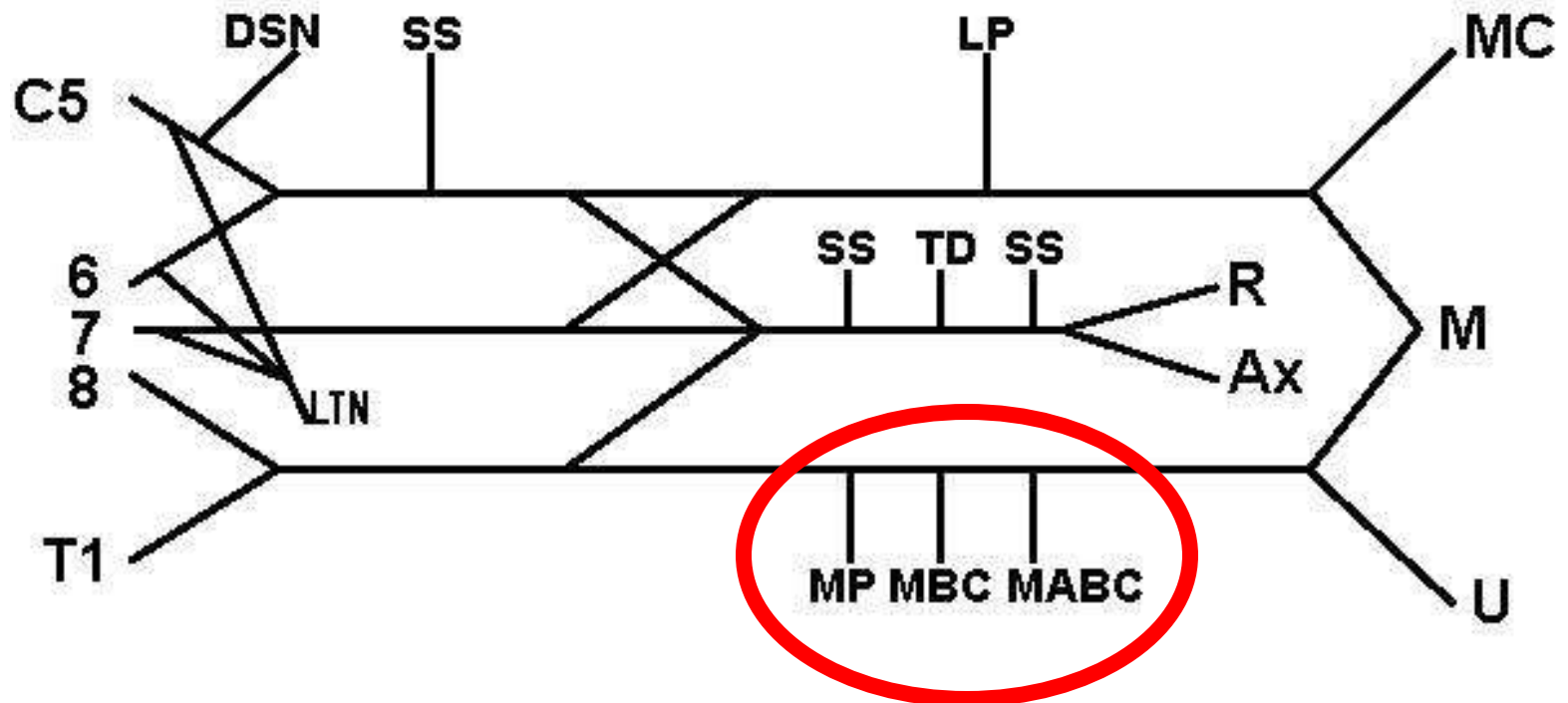
Label the second headless arrow "3":
SS = subscapular
TD = thoracodorsal nerve.



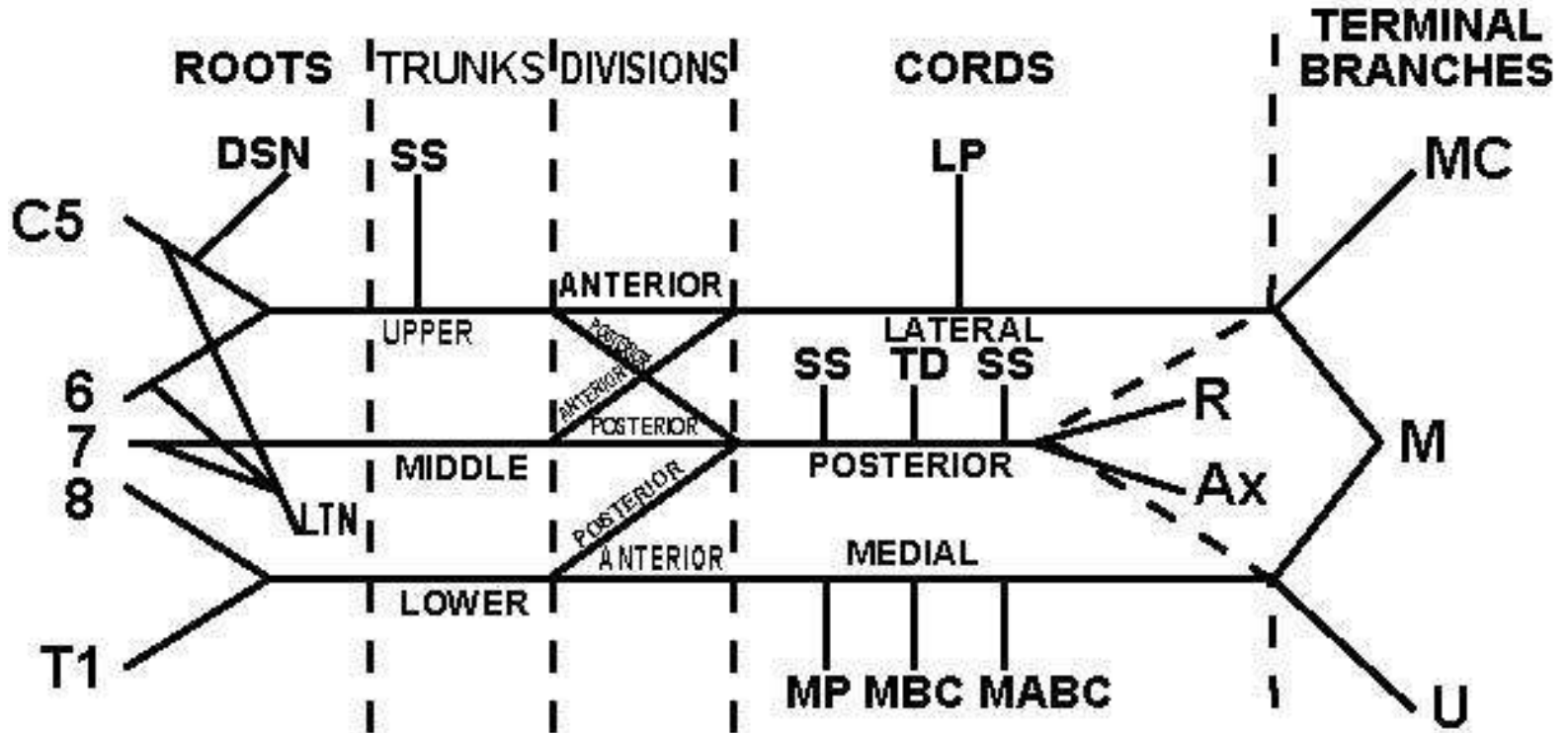
Add the final "3" on the bottom headless arrow.



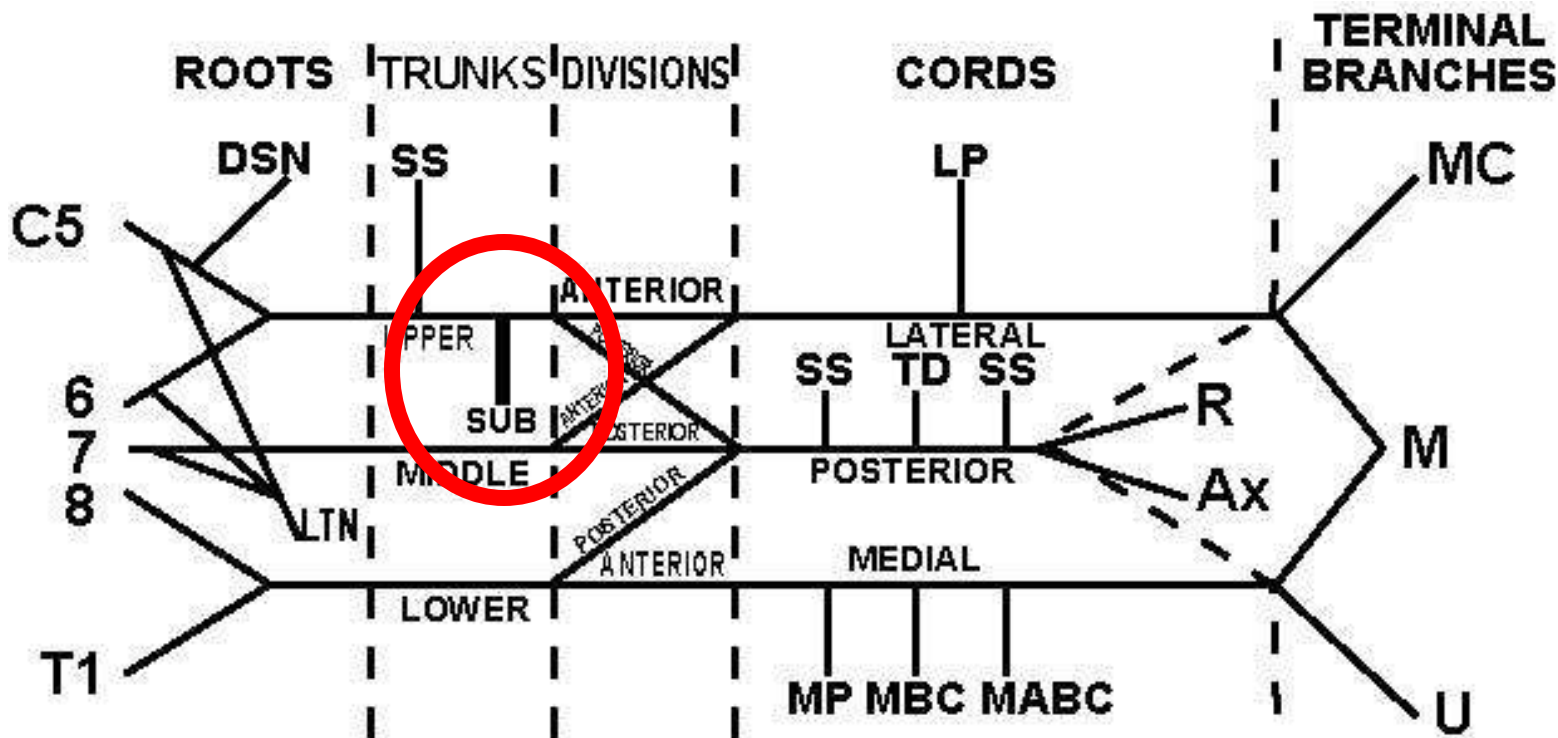
Label the last "3." MP = medial pectoral, MBC = medial brachial cutaneous, and MABC = medial antebrachial cutaneous. Remember: the brachial cutaneous goes to the brachium or arm, and the MABC goes to the antebrachium or forearm. The nerve to the forearm starts distally.



Label roots, trunks, divisions, cords, terminal branches.



Radiologists, neurosurgeons and thoracic surgeons need to know the nerve to the subclavius (SUB).



The complete brachial plexus diagram:

